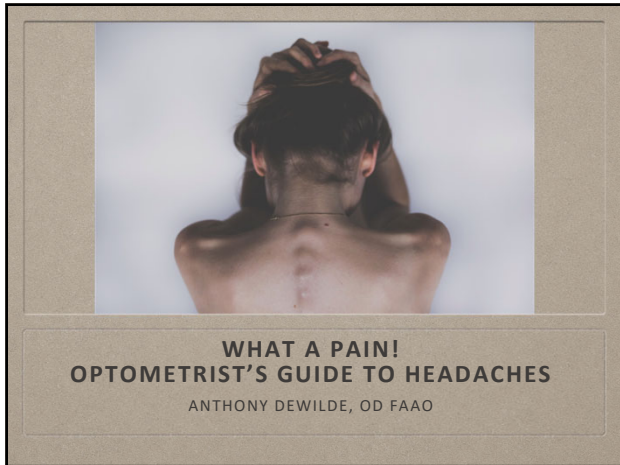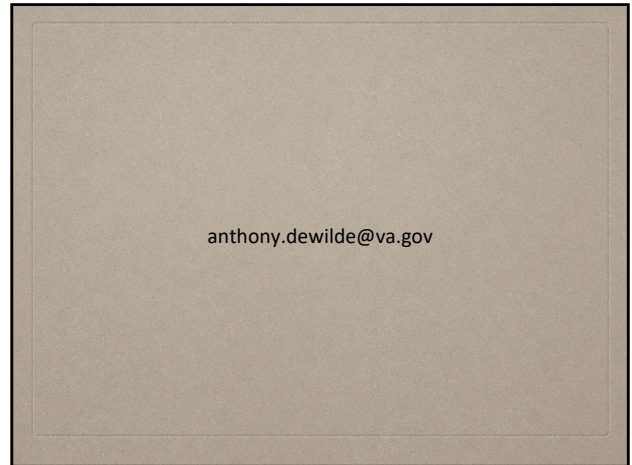
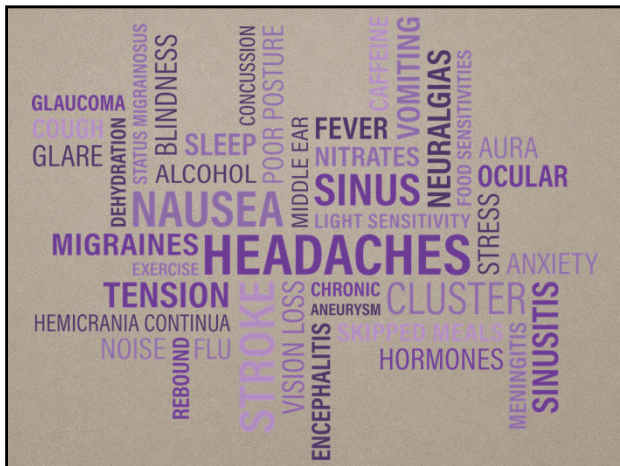


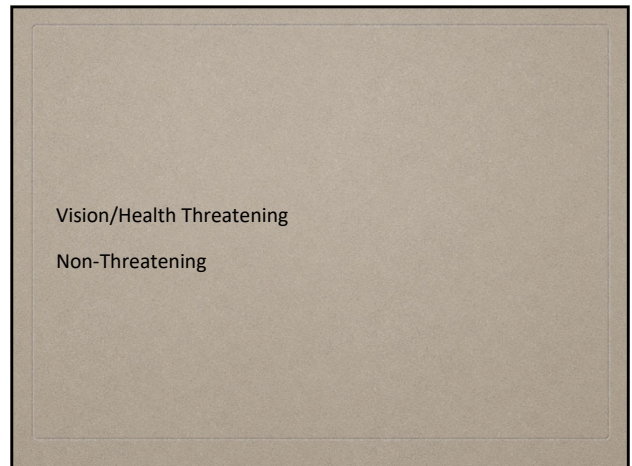
1



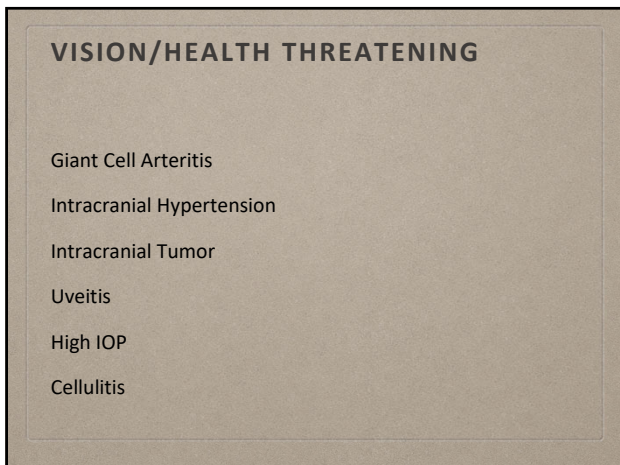
2



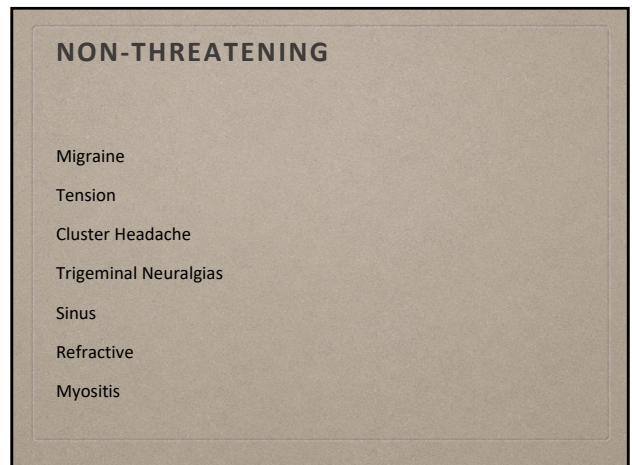
3



4



5



6



7

## EXAMINATION

### Thorough Case History

Onset?

Duration?

Location?

What helps?

8

## EXAMINATION

### Thorough Evaluation

Refraction

BV Testing

IOP

Anterior Segment

Optic Nerves

9

## EXAMINATION

### Thorough Evaluation - usually referral


Laboratory Tests

Brain Imaging (CT/MRI)

Lumbar Puncture

10

## REFRACTIVE



Latent Hyperopia

Miscorrected Refractive Error

11

## BV TESTING

Phorias/Vergence


NRA

PRA

12

**OCULAR HEALTH**

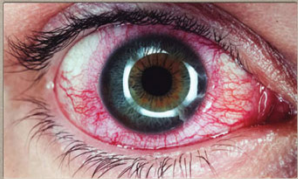
IOP  
Consider Gonioscopy



13

**OCULAR HEALTH**


Any Cells in A/C?



14

**OCULAR HEALTH**


Cellulitis  
Warm to touch  
+ APD  
Vision Loss



15

**OCULAR HEALTH**


Pain on eye movement  
Possible myositis



16

**OCULAR HEALTH**

Optic Nerve Edema?  
Unilateral?  
Bilateral?



17


**OPTIC NERVE EDEMA**

GCA  
Intracranial HTN  
Intracranial Tumor  
Optic Neuritis

18

**GCA**

50+ Years  
 Temporal Headache  
 Neck Pain  
 Jaw Claudication



ATION FOR MEDICAL EDUCATION AND RESEARCH. ALL RIGHTS RESERVED

19

**GCA**

Labs  
 ESR, CRP, CBC


Temporal Artery Biopsy

Rheumatology Consult

20

**GCA**


Treated with  
 Steroid (long taper)  
 Steroid Sparing  
 Methotrexate  
 Actemra



21

**ZOSTER**

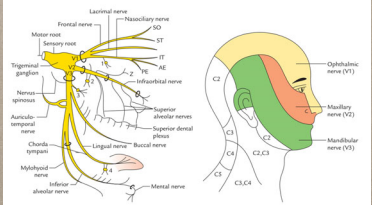
Can Masquerade  
 Unilateral facial pain  
 Vesicles  
 Difficult to diagnose early



22

**ZOSTER**

80% involve V1



23

**ZOSTER**

“Wild Type” Zoster  
 Vaccination Zoster

24

## ZOSTER

Primary Care Provider  
Need Acyclovir/Valacyclovir/Famciclovir  
May need IV

25

## ZOSTER

If Ocular involvement - treat 2 weeks oral  
  
Post Herpetic Neuralgia  
Gabapentin/Lyrica

26

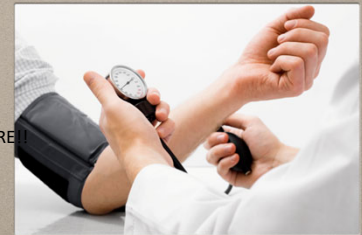## ZOSTER

Vaccination  
Zostavax  
Shingrix — CDC recommends 50+ years old

27

## INTRACRANIAL HYPERTENSION

CHECK BLOOD PRESSURE



28

## INTRACRANIAL HYPERTENSION

Bilateral Optic Nerve Edema  
Typically Young Obese Women\*  
Pulsatile Headache  
Tinnitus  
Cranial Nerve VI Palsy

29

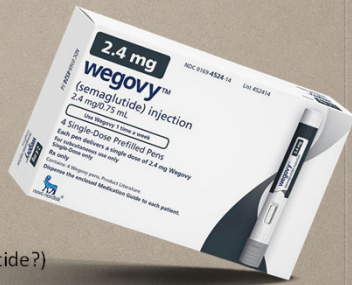
## INTRACRANIAL HYPERTENSION

Need MRI/MRV  
Blood Pressure  
Lumbar Puncture

30

### INTRACRANIAL HYPERTENSION

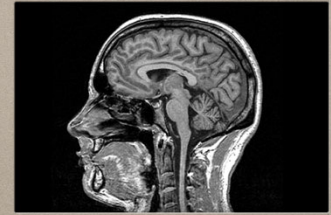- Treated with
- Pain meds
- Diamox
- VP Shunt
- Weight Loss (Semaglutide?)



31

### INTRACRANIAL TUMOR

- Unilateral or Bilateral
- MRI or CT
- Takes up intracranial space



32

### TENSION HEADACHE

- Related to
- Stress
- TMD\*
- Posture
- Hydration



33

### TENSION HEADACHE

- 30 minutes - 7 Days
- At least two of the following four characteristics:**
- bilateral location
- pressing or tightening (non-pulsating) quality
- mild or moderate intensity
- not aggravated by routine physical activity

34


### TENSION HEADACHE

- Treated with
- NSAIDs
- Lifestyle
- Massage
- TMD treated

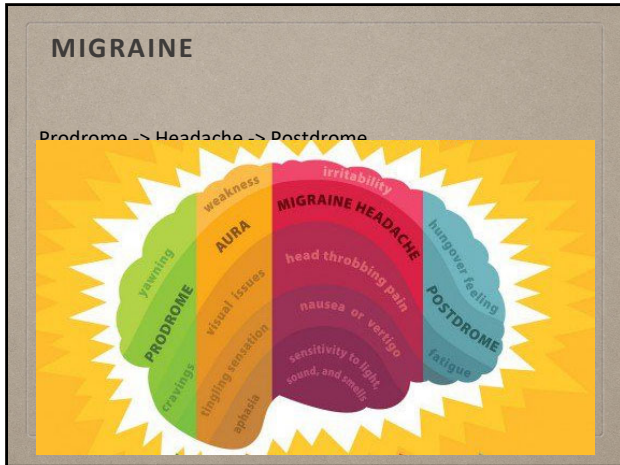
35

### MIGRAINE

- 38 Million in USA
- Ages 15-55
- Women 2x more



36

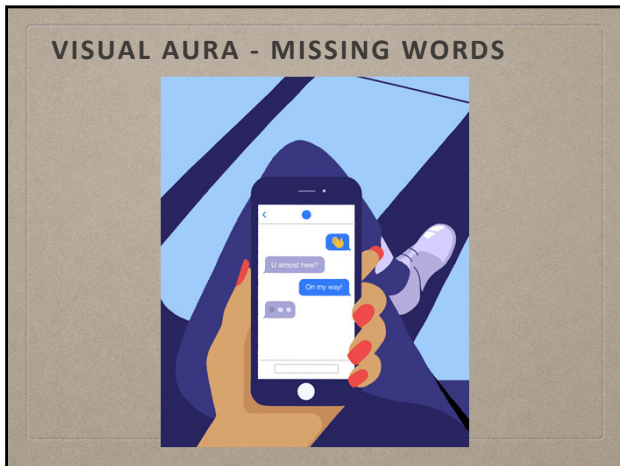


37

### MIGRAINE

- Unilateral
- Nausea
- Vomiting
- Light and Sound sensitive


38




39




40



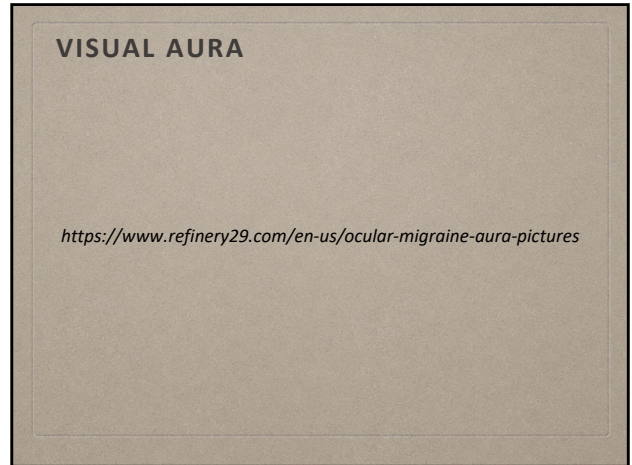
41




42



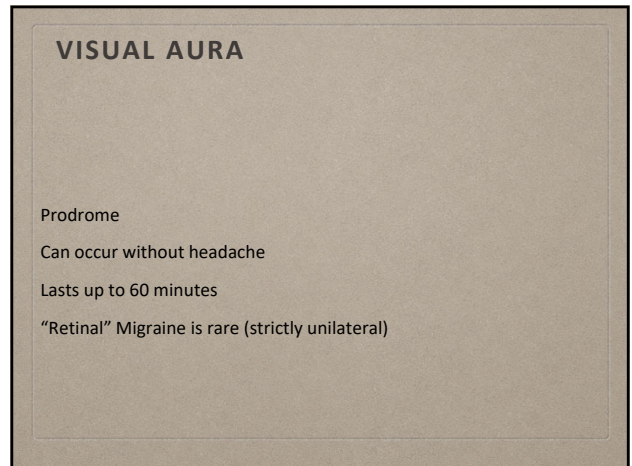
43



44



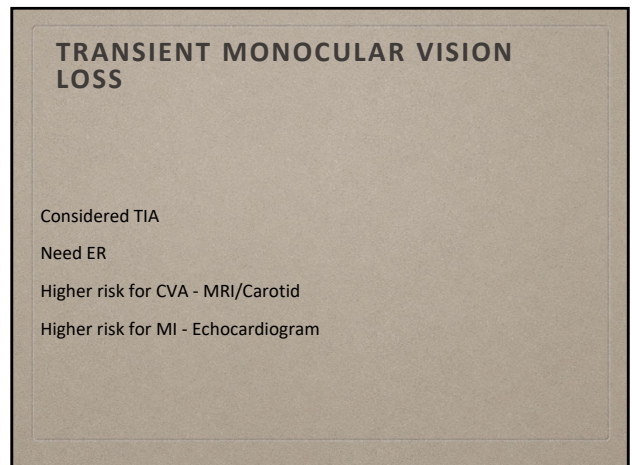
45



46

Visual Aura	Amaurosis Fugax
5-30 minutes	Seconds - days
Bilateral	Unilateral
Blur/kaleidoscope	Dim/gray
Central -> Moving	Altitudinal

47



48



**MIGRAINE**

**Preventative**

- Lithium
- Valproic Acid
- Topamax
- Beta Blocker
- Trigger avoidance

49

**MIGRAINE**

**Abortive**

- NSAID
- Caffeine
- Triptans



50

**MIGRAINE**

**New Therapies**

- Botox
- Occipital Nerve Block
- Sphenopalatine Ganglion Block
- Anti-CGRP (Calcitonin Gene Receptor Peptide)

51

**MIGRAINE**

**CGRP Medications**



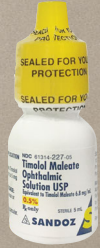
52

**Timolol Eye Drops**

1 drop eye eye Timolol 0.5%

Pain reduction in 82% of patients

Can help with aura



*JAMA Ophthalmol. 2020;138(11):1160-1166.  
doi:10.1001/jamaophthalmol.2020.3676*

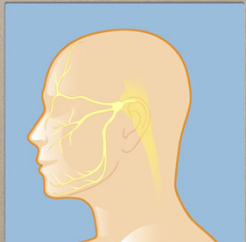
53

**TRIGEMINAL AUTONOMIC CEPHALALGIA (TAC)**

Cluster Headache

SUNCT

Paroxysmal Hemicrania



54

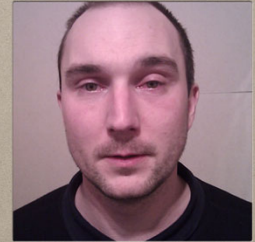**CLUSTER HEADACHE**

Rare unilateral headache  
 VERY Painful "Suicide Headache"  
 Sharp/Stabbing pain behind eye  
 Wake patient up

55

**CLUSTER HEADACHE**

Horner's  
 Unilateral  
 Pupil constriction  
 Ptosis  
 Epiphora



56

**CLUSTER HEADACHE**

May get MRI  
 Diagnosed by symptoms  
 Refer to Neurology

57

**PREVENTIVE**

Verapamil  
 Lithium  
 Beta Blocker  
 Steroids  
 CGRP

58

**ABORTIVE**

Triptans - Pill, Nasal Spray, Subcutaneous

Oxygen  
 Nerve Block  
 CGRP



59


**SHORT-LAST UNILATERAL NEURALGIFORM HEADACHE WITH CONJUNCTIVAL INJECTION AND TEARING (SUNCT)**

Unilateral  
 Burning/stabbing/electric  
 Behind eye  
 Lasts 5 seconds - 6 minutes  
 Up to 200x/day  
 Have autonomic changes

60

## SUNCT/SUNA

### Autonomic symptoms associated with SUNCT/SUNA



- LACRIMATION (TEARING)
- CONJUNCTIVAL INJECTION (BLOODSHOT EYES)
- PTOSIS (DROOPING EYE)

PRAxis

61

## SUNCT/SUNA

Treated with

- Anti-seizure meds
- Steroids
- NSAIDs
- Nerve pain meds

62

## PAROXYSMAL HEMICRANIA

Throbbing/boring pain

Behind eye

Last 2-3 minutes

5-40 x/day

63

## PAROXYSMAL HEMICRANIA

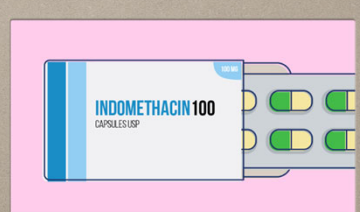
A	At least 20 attacks fulfilling criteria B–E
B	Severe unilateral orbital, supraorbital, and/or temporal pain lasting 2 to 30 minutes
C	Either or both of the following: <ol style="list-style-type: none"> <li>At least one of the following symptoms or signs ipsilateral to the headache:               <ol style="list-style-type: none"> <li>Conjunctival injection and/or lacrimation</li> <li>Nasal congestion and/or rhinorrhea</li> <li>Eyelid edema</li> <li>Forehead and facial sweating</li> <li>Miosis and/or ptosis</li> </ol> </li> <li>A sense of restlessness or agitation</li> </ol>
D	Occurring with a frequency of > 5 per day
E	Not better accounted for by another ICHD-3 diagnosis
F	Prevented absolutely by therapeutic doses of indomethacin

64

## PAROXYSMAL HEMICRANIA

Indomethacin!!

Can resolve on its own



65

## EXAMINATION

**Thorough Case History**

- Onset?
- Duration?
- Location?
- What helps?

66

## EXAMINATION

### Thorough Evaluation

Refraction

BV Testing

IOP

Anterior Segment

Optic Nerves

67

## CHARACTERISTICS

	Migraine headache	Tension headache	Cluster headache
<b>Character</b>	Unilateral; throbbing, hammering	Bilateral; dull, "band-like" compression	Unilateral; piercing, stabbing, burning
<b>Course</b>	Slowly progressing headache that may last up to 72 hours	Initially episodic, may progress to chronic form with daily headaches	Clustering of attacks lasting for weeks followed by periods of remission (75% of cases)
<b>Additional symptoms</b>	Often accompanied by nausea/vomiting, photophobia/phonophobia. Aura phenomena may occur	Photophobia/phonophobia may occur, <b>no</b> nausea, <b>no</b> vomiting	Autonomic symptoms (lacrimation, rhinorrhea, sweating)
<b>Note</b>	♂ > ♀; age of onset: 15-25 years; exercise/exacerbates headache	♂ > ♀; age of onset: 30-40 years; exercise <b>does not</b> exacerbate the headache	Attacks often occur at night ♂ > ♀; age of onset: 20-40 years; short duration of attacks (30-40 min)
<b>Remember</b>	High risk of medication overuse headache	Autonomic symptoms are absent	

68

anthony.dewilde@va.gov

69